

## Research Article

# ACCURACY OF USG IN STRATIFYING PALPABLE BREAST LESIONS: CORRELATIVE STUDY USING FINE NEEDLE ASPIRATION FOR CYTOLOGY

JHA AK AND SAH RG\*

Department of Radiology, National Medical College Teaching Hospital, Birgunj, Nepal

Email: ranaiims@gmail.com

## ABSTRACT

**Introduction:** The assessment of breast lump is significant to rule out malignancy. Breast cancer is the leading cause of death of women with more than one million cases occurring worldwide annually. No consistent data regarding incidence and prevalence of carcinoma of breasts in Nepal is available.

**Objective:** Thus, the objective of this study was to evaluate the sonographic features of different breast lumps and to correlate the various Ultrasonography (USG) characteristic features with fine needle aspiration for cytopathology (FNAC) in order to affirm whether this distinction could be definite enough to obviate biopsy.

**Methods:** The study was conducted in 47 patients with palpable breast lump.

**Results:** Out of the 47 cases, 34 cases (77.27%) were diagnosed as benign in USG while the 9 cases (20.45%) were diagnosed as malignant. One case was found as intermediate in USG. FNAC was correlated in all the cases. Among 9 cases diagnosed as malignant in USG, FNAC conformed only 8 cases to be malignant. Thus, one cases (2.27%) diagnosed as a benign in USG turned out be malignant in FNAC. Two cases were diagnosed as cyst and three as abscess in USG exactly matched (100%) with FNAC diagnosis. The correlation between USG and FNAC showed the sensitivity of 88.89% with specificity of 97.06%. The positive predictive and negative predictive values were found to be 97.06% and 88.89%, respectively ( $p < 0.05$ ).

**Conclusion:** The result of present study measured the outcome of this research in perspective of Nepal, as a useful imaging tool for diagnosing breast lumps and characterizing benignity and malignancy.

**Keywords:** Floating Breast lump, ultrasonography, benign, malignant, echogenicity, calcification, FNAC.

## INTRODUCTION

Breast diseases are generally found to be common in females (99.3%) compared to man (0.7%) [1]. In developing countries like Nepal, females are unaware of breast pathologies because of social taboo and are hesitant to reveal, hence it is detected usually in advanced stages. Some of the common pathologies of breast are various benign breast lesions e.g fibroadenomas, cyst, abscess, galactoceles, duct ectasia, enlarged lymph nodes and different malignancies.

Among them breast malignancies is most common cause of cancer death in women and overall fifth common cause of cancer deaths in the world<sup>2</sup>. It is the second most common malignancy among women in Nepal. It is a heterogeneous disease with no single cause. Delay in the detection causes malignancy to progress in advanced stage which comprises of inoperable masses, metastasis (bone, brain, lung) and is a significant cause of morbidity and mortality worldwide<sup>3,4</sup>. Breast lesions at ultrasound have a number of characteristics which allows classification as malignant and benign. The differentiation between malignant and benign lesions, screening of younger age group women, identifying lesions in a fatty breast, identifying recurrence lesion, monitoring tumor response to therapy, etc. are some of the vital clinical issues to be addressed. Still, large numbers of breast lesions cases remain unreported due to lack of awareness, education and lack of facilities in people residing in rural areas. Early diagnosis and treatment are important to decrease the morbidity and mortality. Benign breast diseases need early detection and management because of its high prevalence and its cancerous potential (3-5%). Thus, early detection, diagnosis, and screening of breast lesions have a significant impact on patient management like treatment outcome and survival.

Imaging is required for the diagnosis, appropriate treatment decision and proper follow up. Treatment modality depends upon the extent of the disease and tumor biology. However, there is a strong need for standard guidelines for the proper management of breast cancer in Nepal so that

surgery, chemotherapy, hormone therapy and radiotherapy are standardized in the country. Palliative care has been initiated to provide to some patients with metastatic breast cancer recently. The diagnosis of breast lesion is generally based on physical examination, X-ray mammography, USG and FNAC. **X-Ray mammography** is the first line of technique used for primary detection and screening of breast cancer with sensitivity between 69% and 90% but with variable specificity in many countries [5]. However, it is reported that this technique has false negative rate (misses lesion) around 10% to 25% in detecting breast cancers in dense breast [6]. In addition, mammogram limitation includes exposure to ionizing radiation. **Fine needle aspiration cytology (FNAC)** is considered the gold standard method, cost effective and useful for mass lesions [7,8,9]. It has a sensitivity and specificity of > 90% and > 65%, respectively. The positive predictive value was reported to be > 99%<sup>10</sup> depending on the skill of person performing the aspiration and expertise of the cytopathologist [11]. Sometimes the problematic cells are missed, resulting in a false negative result. Further, FNAC cannot reliably predict invasion of tumor [12], additionally there is difficulty in assessing deep seated lump within the breast and it is an invasive procedure as well. Thus, breast **Ultrasonography (USG)** has evolved as an indispensable problem solving tool in patients with dense breasts, post-radiation breasts, and women less than 35 years of age, pregnant and lactating patients [13]. It is an important technique adjunct to mammography and clinical examination in assessing impalpable breast abnormalities and mammographically occult lesions [14,15]. It differentiates cystic from solid lesions; benign and malignant breast neoplasm in women when mammography is less sensitive due to dense breasts. The sensitivity of detecting cancer is reported as 65% and 92% [16]. Keeping these vital clinical issues in apprehension we decided to conduct this study in the Nepalese group of women.

## Objectives

1. To evaluate the sonographic features of different breast lumps and analyze the feasibility of ultrasonic diagnosis.

2. To assess the reliability of USG features of malignancy and
3. To correlate the various ultrasonography characteristic features of breast lumps with cytopathology (FNAC) and to evaluate whether this distinction could be definite enough to obviate biopsy.

## MATERIAL AND METHODS

A prospective study was performed by enrolling patients with clinically diagnosed lumps from Gynecology/ Surgical/ Medical OPD or those who were admitted in the ward. The study was conducted according to the rules and regulations of ethical regulatory board of our Institution, National Medical College Teaching Hospital, Birgunj, in Radio-diagnosis department. The written informed consent was obtained from each patient before the study entry. The patients included were of more than 16 years of age with breast lumps and were willing to undergo both USG and FNAC procedures. Patients with, inflammatory breast cancer, radial scar, on prior treatment, recurrent lump, metastatic disease, who were pregnant, palliative intent and also those not willing to take part for both the procedures in the study were excluded. Patients were

evaluated by triple assessment that comprises of clinical history and physical examination, radiology (ultrasonography), and pathology (fine needle aspiration cytology) evaluation. A total of 47 patients were recruited for the study. Of the 47, statistical analysis was carried out on 44 patients. Three of them were excluded due to unavailability of the cytopathology report because of the inadequate sample. Out of 44, thirty four were with benign breast pathology (mean  $\pm$  SD age,  $31.8 \pm 9.7$  years, range; 16 - 61 years); nine cases (mean  $\pm$  SD age,  $45.3 \pm 10.2$  years, range; 25 - 75 years) were diagnosed as malignant and one (38 year) was diagnosed as intermediate in USG the clinical details of these patients are given in Table 1. Clinical evaluation of lumps was performed in all the cases which include history regarding appearance of the lumps, pain, discharge, duration of symptoms, presence of other conditions, etc. The entire patients underwent USG examination with using a high resolution frequency (7.5MHz) linear array transducer (Aloka 1300 machine). USG features were documented prior to subjecting the patient for FNAC. After USG examination and diagnosis, FNAC was performed under USG guidance by the radiologist and pathologist from department of pathology.

**Table 1: categorization of breast lump based on USG diagnosis Ultrasonography Diagnosis.**

Age gr. Pt (in years)	Fibroadenoma	Cyst	Intermediate	Malignancy	infective	Total no cases
16-20	6	0	0	0	0	6
21-30	16	1	0	0	3	20
31-40	5	1	0	1	0	7
41-50	1	0	1	4	0	6
51- above	1	0	0	4	0	5
Total	29	2	1	9	3	44

## Method for USG guided FNAC

After the lump was located under guidance of USG, it was fixed in position with one hand. Under aseptic precaution a 20 ml syringe fitted with 18 to 22 gauge needle was used to puncture the lesions. Vacuum was applied to the syringe by pulling the plunger and the needle was moved back and forth a few times within the lesion under USG.

**Table 2: The 2 by 2 table showing sensitivity, specificity, Negative predictive value, Positive predictive value and accuracy in n=43 cases.**

Cases	Benign	Malignant	Total
Positive USG Diagnosis	8 (TP)	1 (FP)	9
Negative USG Diagnosis	1 (FN)	33 (TN)	34
Total 43	9	34	43

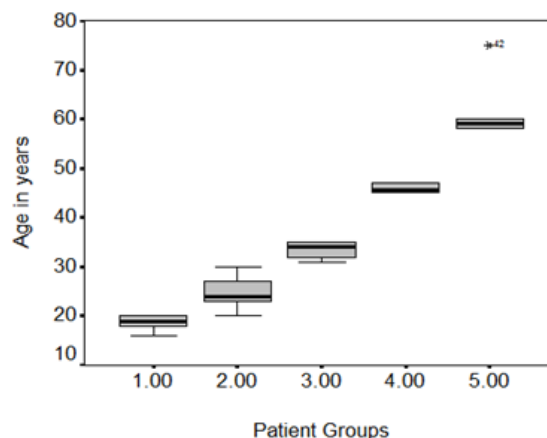
## Statistics

Finally, both the diagnosis was compared. All the statistical analysis was carried out in SPSS 16.0. Patient's age (in each group) was calculated using parametric one way ANOVA test. The predictive values (sensitivity, specificity, positive predictive value, negative predictive value and accuracy) of USG between benign and malignant groups of breast lesion were calculated using 2 by 2 table. A  $P < 0.05$  was considered to be statistically significant.

## Results

The results presented here are based on the observation of each characteristic feature of breast lesions detected in USG and finally correlating them with FNAC diagnosis. All the cases of breast lump were diagnosed with USG were subjected to fine needle aspiration for cytology (FNAC). Finally, A total of 44 the findings of USG were compared with the findings of FNAC.

The mean age of the patient was  $32.84 \pm 13.71$  (16-75) Years. Based on age all patients were divided into 5 groups, age group 1 represent 16-20 yrs which is 14% of total patients; group 2 represents 21-30 yrs, 45% patients; group 3 represents 31-40 yrs, 16% patients; group 4 represents 41-50 yrs, 14% patients and the latest group represents 51 yrs and above, 11% patients (see Figure 1). Patient's age in each group was found to be statistically significant ( $P < 0.001$ ) using Parametric one way ANOVA test.



**Figure 1: Box plot represents age of patients in years in each groups with  $P < 0.001$ .**

## Occurrence of lump by side of the breast

The occurrence of lump based on side of the breast was calculated which shows 66% of cases had left-sided lump, 30% had right-sided lump and 4% had bilateral lumps.

## Echogenecity pattern in USG

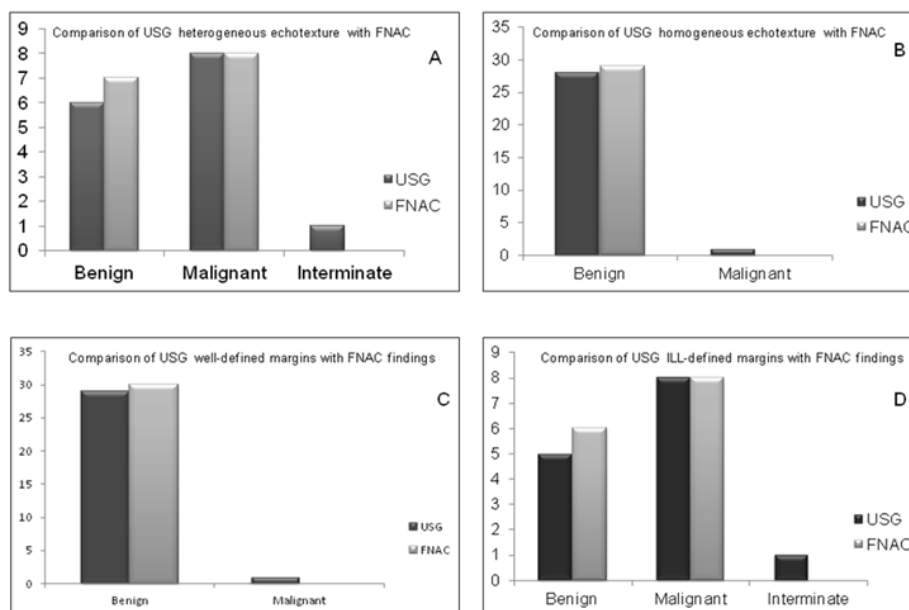
Based on echogenecity the result showed 64% of cases (28 cases) had homogeneous echo pattern while 36% of cases (16 cases) had heterogeneous echo pattern.

## Comparison of USG and FNAC diagnosis, in cases of echotexture and margins diagnosed by USG

As shown in the Figure 2 (A), in sonological heterogeneous echo texture, USG had diagnosed 6 cases as benign while FNAC had diagnosed 7 cases. Similarly, 8 cases have been diagnosed as malignant in USG while FNAC diagnosed 9 cases to be malignant. Two cases which did not match the FNAC diagnosis. In total 16 cases with heterogeneous echo texture, 14 cases (88%) of USG diagnosis matched exactly with the FNAC diagnosis.

While, in cases of sonological homogenous echotexture, USG had diagnosed 27 cases as benign while FNAC had diagnosed 28 cases as benign. Similarly, 1 case had been diagnosed as malignant in USG but

no case was found to be malignant in FNAC [Figure 2 (B)]. In total 28 cases with homogenous echotexture, 27 cases (96.42%) of USG diagnosis matched exactly with the FNAC diagnosis.



**Figure 2:** The bar diagram represents comparison of USG and FNAC diagnosis based on echotexture and margins diagnosed by USG (A) heterogeneous echotexture; (B) homogenous echotexture diagnosed by USG; (C) well-defined margins; (D) ILL-defined margins diagnosed by USG.

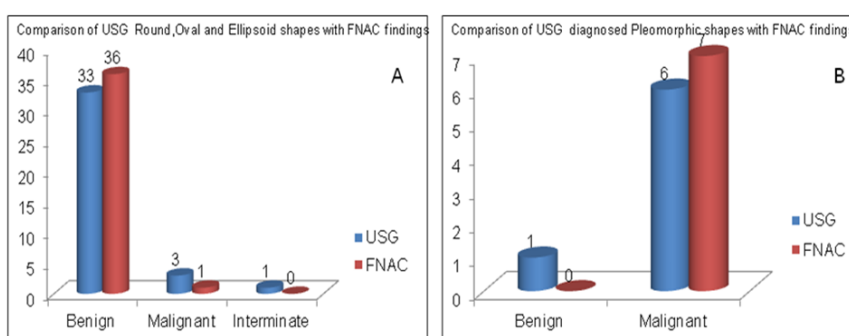
The Figure 2 (C) shows among 30 cases with sonologically well-defined margins, USG diagnosis was 29 benign lesions and 1 malignant lesion while FNAC diagnosed all the 30 cases to be benign. One case diagnosed as malignant in USG and no case was found to be malignant in FNAC. In total 30 cases with well-defined margin, 29 cases (96.67%) of USG diagnosis matched exactly with the FNAC diagnosis. One case turned out to be benign in FNAC which was diagnosed as malignant in USG.

As is evident in Figure 2 (D) among 14 cases with sonologically ill-defined margins, USG diagnosis was 6 benign lesions and 7 malignant lesions whereas; FNAC diagnosed 6 cases as benign lesions and 8 malignant lesions. One case was diagnosed as indeterminate in USG. In total 14 cases with ill-defined margin, all the 6 cases of USG diagnosis matched exactly with the FNAC diagnosis for benign lesions while 1

case was under diagnosed in USG compared to FNAC. One case turned out to be benign in FNAC which was diagnosed as indeterminate in USG.

#### Comparison of USG and FNAC diagnosis of the lesions based on sonologically detected shapes

Among 37 cases with sonologically oval, round and ellipsoid shape, USG diagnosis was 33 benign lesions and 3 malignant lesions while FNAC diagnosed as 36 benign and 1 malignant lesions. One case was diagnosed as indeterminate in USG as shown in Figure 3 (A). In total 37 cases with round, oval and ellipsoid shape, 33 cases (91.67%) of USG diagnosis matched exactly with the FNAC diagnosis for benign lesions while 3 cases diagnosed as malignant in USG, only one case was diagnosed as malignant in FNAC diagnosis, i.e., 33.33% matched.



**Figure 3:** The bar diagram represents comparison of sonologically detected shapes with FNAC findings (A) Sonologically detected Round, Oval and Ellipsoid shapes; and (B) Sonologically detected Pleomorphic shaped lesion with FNAC findings.

Figure 3 (B) shows among 7 cases with sonologically pleomorphic shape, USG diagnosis was 1 benign lesion and 6 malignant lesions while FNAC diagnosed as all the 7 cases to be malignant. Hence, 6 cases (85.71%) matched with FNAC diagnosis of malignancy.

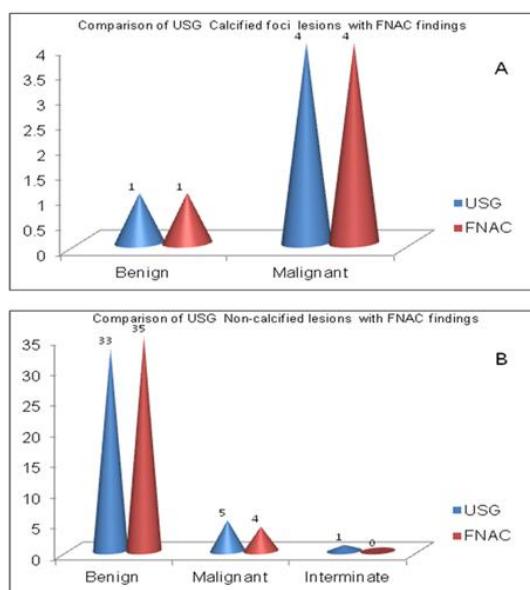
#### Comparison of USG and FNAC diagnosis based on sonologically detected calcified and non-calcified lesions

Among 5 cases with sonologically calcified foci, USG diagnosis was 1 infective which is considered as benign for shake of convenience which

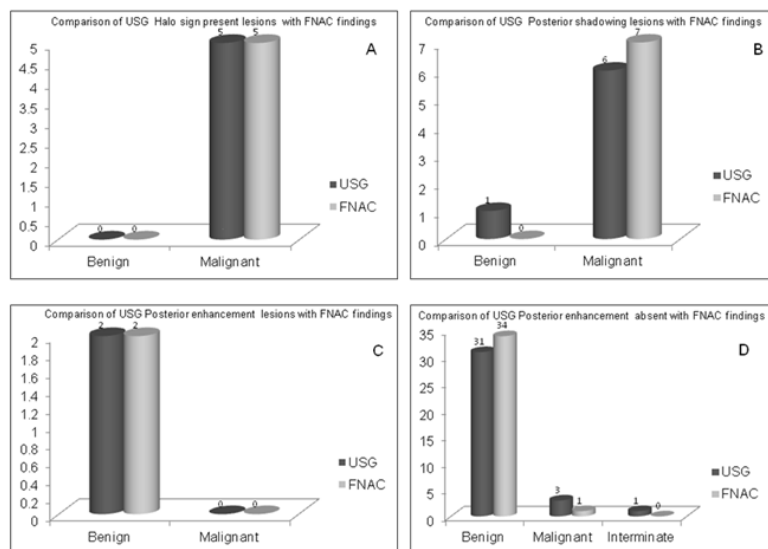
matched exactly that of FNAC diagnosis and 4 were diagnosed as malignant in USG which also matched with the FNAC diagnosis [see Figure 4 (A)].

The Figure 4 (B) depicts that among 39 cases with sonologically noncalcified lesion, USG diagnosis were 33 benign and 5 malignant. One case was diagnosed as indeterminate in USG. However, FNAC showed 35 cases to be benign and 4 cases to be malignant. So, 94.29%

benign USG diagnosis matched with FNAC; 80% of malignant USG diagnosis matched with FNAC.



**Figure 4: The bar diagram represents the comparison of sonologically detected (A) Calcified and (B) Non-calcified lesions with FNAC findings.**



**Figure 5: The bar diagram represents the comparison of sonologically detected (A) halo sign present lesions; (B) posterior shadowing present lesions; (C) posterior enhancement present and (D) posterior enhancement absent lesions with FNAC findings.**

#### Comparison of USG and FNAC diagnosis based on AP and transverse dimensions detected lesions on USG

All the benign lesions diagnosed by USG, mean AP diameter (3.16 cm) is less than mean transverse diameter (3.97 cm) while in malignant lesion mean AP diameter (4.01 cm) is more than mean transverse diameter (3.87 cm)

#### Comparison of USG and FNAC diagnosis based on lymphadenopathy detected on USG

In all cases of lymph node enlargement, the USG diagnosis was malignant which matched exactly with FNAC diagnosis.

The sensitivity, specificity, negative predictive value, positive predictive value and accuracy of USG in (n=43) cases was calculated using 2 x 2 table. The result shows sensitivity of 88.89% with of specificity: 97.06%. The negative predictive value was 97.06% while, positive

#### Comparison of USG and FNAC diagnosis based on halo sign present, posterior shadowing and posterior enhancement lesions present or absent

The Figure 5 (a) shows, among 5 cases with halo sign noted on USG, no cases were diagnosed as benign in USG as well as FNAC while 5 cases were diagnosed as malignant in USG matched exactly with the FNAC diagnosis. Hence, 100% diagnosis matched in benign as well as malignant lesions.

Among 7 cases with posterior shadowing noted on USG, 1 case was diagnosed as benign in USG and no case was diagnosed as benign in FNAC while 6 cases were diagnosed as malignant in USG and 7 cases were diagnosed as malignant in FNAC as evident in Figure 5 (B). 85.71% of malignant diagnosis in USG matched with FNAC diagnosis.

The Figure 5 (C) reflects that among 2 cases with posterior enhancement noted on USG, both cases were diagnosed as benign in USG as well as in FNAC. No case was found malignant in USG as well as in FNAC. Hence, 100% of diagnosis in USG matched with FNAC diagnosis.

Among 35 cases with posterior shadowing absent noted on USG, 31 cases were diagnosed as benign and 3 as malignant in USG whereas FNAC showed 34 cases as benign and 1 as malignant. One was diagnosed indeterminate in USG [see Figure 5 (D)]. Hence, 91.17% diagnosis of benign cases matched with that of FNAC, and 33% diagnosis of malignant cases in USG matched with that of FNAC.

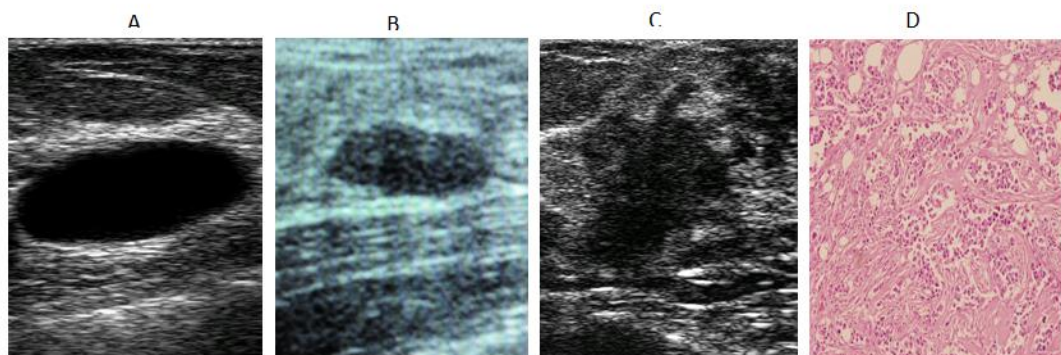
predictive value was 88.89% and the accuracy was found to be 97.67% (see Table 2).

#### DISCUSSIONS

The manifestation of any lump in the breast is a highly significant and warrants a comprehensive investigation. Ultrasound has potential of visualizing and detecting differences in the appearance of different breast lesions. It is highly accurate in the benign/ malignant differentiation of breast masses [14,17] and is useful in predicting the invasive extent of breast cancers in many cases [18]. The present study was conducted to study the precision of ultrasonography in the diagnosis of palpable breast lumps. The result showed US features that most reliably characterize lesion as benign were a round or oval shape were (91.67%); with well circumscribed margins (96.67%); absent of halo sign (100%), posterior enhancement (100%) in cases of cyst; posterior shadowing and lymph node enlargement absent (91.17%). Also a mean anteroposterior

diameter 3.16 cm is less than mean transverse diameter (3.97 cm) was considered as benign. While, features that characterize masses as malignant included pleomorphic shapes (irregular shape); (85.71%) irregular (ill defined) margins (100%); calcified foci noted (100%) whereas non-calcified nodule were also noted in 5 malignant cases on

USG out of which 4 (80%) turned to malignant in FNAC; present of halo sign (100%); posterior shadowing noted (85.71%); lymphadenopathy (100%). Further, a mean anteroposterior diameter 4.01 cm is more than mean transverse diameter.



**Figure 6: (A) Shows a well defined anechoic lesion with no evidence of septations or calcification (cyst). (B) A well defined, oval, homogeneously echogenic breast lesion which was diagnosed as fibroadema in USG which correlated with FNAC finding; (C) A typical malignant breast lump showing irregular lobulated shape, ill defined margins and invading adjacent tissues The lump was hypoechoic with heterogeneous echogenicity (FNAC- ductal carcinoma); (D) FNAC showing duct cell carcinoma of breast.**

In a similar study by Rabhar et al. [19] to evaluate the role of USG and FNAC in differentiation of breast lesion, reported the reliable parameters to characterize lesion as benign were round or oval shape (94%) which was similar to our results; well circumscribed margins of 91% in their study also agree with our results. While, the posterior enhancement in their study was found in 78% of the cases whereas we observed in one cystic lesion. While the features that characterize lesion as malignant reported in their literature was 61% irregular shape which was found to be higher (85.71%) in our study. Further, they reported ill defined margins in 47% of the total cases only. This finding doesn't comply with our results which may be due to various reasons as USG being operator dependent. They have not commented on the other parameters like present or absent of calcified nodule, presence or absence of halo sign, lymphadenopathy which are considered as important parameters during differentiation of the breast lesions.

In another similar study by Pande et al. [20] observed round or oval shape in 94%; well circumscribed margins in 90% of the benign cases which was comparable to our findings. While the features like irregular shape and ill defined margins were 100% each, respectively in malignant cases also similar to our results. 100% result reported in cases of irregular margin was same as observed in our study.

In 2005, Watermann et al. [21] published data on the ultrasound features of breast cancer. They found that an irregular shape, indistinct margins and posterior acoustic shadowing were described significantly more often in malignant than in other tumor types (88% versus 67%,  $p < 0.001$ ; 95% versus 76%,  $p = 0.001$ ; 84% versus 58%,  $p = 0.001$ , respectively) [21]. These findings highly comply with our results as we found alike observations in our study as well.

In sonological homogenous echotexture of 29 cases, 96.55% of USG diagnosis matched exactly with the FNAC diagnosis. One case turned out to be benign in FNAC which was diagnosed as malignant in USG. Same result was reported by Rabhar et al. [19] While in heterogeneous echo texture, USG has diagnosed 6 cases as benign while FNAC has diagnosed 7 cases. Similarly, 8 cases have been diagnosed as malignant in USG and these 8 cases were found to be malignant in FNAC as well. One case was diagnosed as indeterminate in USG. In total 15 cases with heterogeneous echo texture, 14 cases (93%) of USG diagnosis matched exactly with the FNAC diagnosis. One case which did not match the FNAC diagnosis was diagnosed as indeterminate in USG. We found no variables that influence the distribution of echogenicity. Our results comply with reports in the literature that also found no significant difference in the groups [22,23].

Further, we also reported in all benign lesions diagnosed by USG, mean AP diameter (3.16 cm) is less than mean transverse diameter (3.97 cm)

while in malignant lesion mean AP diameter (4.01 cm) is more than mean transverse diameter (3.87 cm). This observation had been not reported by other, it require further conformation in a large cohort of patients to establish this features in clinical settings. In one study the authors have reported width to AP dimension ratio greater than (1.4 cm) in benign cases whereas less or equal to 1.4 for the malignant lesion [19].

The features like occurrence of lump based on side of the breast was found more (66%) on had left-sided lump compared to (30%) had right sided lump and 4% had bilateral lumps. Similar observations of breast cancer occurrences in the left breast is more in women were reported by various authors in the literature [24-28]. According to Wilting et al. (2011) [29] mammary carcinoma is 5 - 10% more likely to arise in the left breast. The left side of the body is 10% more prone to melanoma development. Sleeping behavior, handedness, nursing behavior and asymmetric sun exposure were considered as indistinguishable cause. An overview of molecules involved in both processes, focusing on laterality of breast cancer. Several secreted and membrane-bound growth factors such as Nodal, Lefty, FGF, HB-EGF and HGF as well as transcription factors (e.g. Pitx2, FoxA2) may be candidates with such overlapping functions. Moreover, recent results showed that the left side of the body is more prone to melanoma than the right side [30,31]. However, Adesunkanmi et al. (2001) [32] in their study have showed that right side breast lump was involved in 162 patients (72%), while 85(38%) left side and 77(34.2%) bilateral which is contradictory. The current explanations for left-sided breast cancer include handedness and further it warrants study in a large population in this neglected research field [33,34].

Further, predictive value of USG in (n=43) cases was calculated using 2 x 2 table. The result shows sensitivity of 88.89% with of specificity: 97.06%. The negative predictive value was 97.06% while, positive predictive value was 88.89% and the accuracy was found to be 97.67%. The sensitivity of USG in diagnosis of breast lump reported in various studies varied from 94.74 % to 100% [19,20,35-39]. Similarly, a wide variation in the specificity of USG in the diagnosis of malignant breast lesion ranging from 67.8% to 100% have been reported as shown in Table 3 [19,20,35-39]. These wide variations amongst different studies could be due to differences in the parameters used by various authors. It is also reported that the sensitivity has been found to be dependent on the skill and experience of the operator as ultrasound is highly operator dependent technique. Additionally, it may be also due to different inclusion criteria of breast lump (like size, palpable or non palpable) in different studies; inclusion of atypia/ suspicious result as malignant in calculation of sensitivity in some studies; and exclusion of inadequate results in some studies.

**Table 3: The diagnosis of USG in predicting sensitivity, Specificity, PPV and NPV in the various studies from literature**

Studies	Total No. of cases (n)	No. of malignant cases	Sensitivity (%)	Specificity (%)	Positive predictive value	Negative predictive value
Englewood USA 1995	750	125	98.4	97	NA	NA
Yang et al. 1996	408	67	97	97	85	NA
Royal UK et al. 1990	60	23	96	84	NA	NA
Pande et al. 2003	36	20	95	94.1	95.50	93.75
Stavros et al. 1995	750	125	98.4	67.8	38	99.5
Skaane et al. 1998	336	200	100	NA	NA	100
Soo et al 2001.	420	70	NA	NA	NA	99.8
Takhellambam et al. 2013	60	22	94.74	100	100	97.22
Jan M et al. 2012	200	15	100	96.4	66.7	100
Our Study	44	9	88.89	97.06	97.06	88.89

When we calculated predictive values of USG after comparing with FNAC in the diagnosis of malignancy in breast mass, both the specificity and negative predictive value was found to be 97.06%. Thus the ability of USG to detect positive cases correctly (malignant report) can be considered confirmatory and further treatment decision can be made solely on this report without any further additional diagnostic investigation. A sensitivity result of USG of 88.89% in our study suggests that a negative (benign) result of USG does not completely rule out the possibility of malignant nature of the mass. Hence, in the event of a negative result (benign report) physician should seek for additional investigations to rule out malignancy should utilize his clinical skill and experience to assume malignant nature of the lump. In this circumstance of USG findings 11.11% cases having malignant lesion would be missed if USG was solely used for evaluation of breast lump. Similarly a specificity of 97.14% of USG means that a positive (malignant) result of USG does not completely rule out the possibility of benign nature of the lesion. However, the percentage of indeterminate result was also found in USG (1 out of 44) compared to FNAC. In addition three breast masses could not be characterized. One case of indeterminate USG result was correctly diagnosed as malignant by FNAC. Thus, both the diagnostic tools should be considered complementary and the physician should use the basis of his clinical findings and experience in choosing either one of or both the tools in diagnosing is of paramount importance.

In a similar study by Reinikainen et al. (1999) [40] to evaluate the role of USG and FNAC in the diagnosis of palpable solid breast lesions, they retrospectively reviewed the mammograms and ultrasound images of 84 palpable breast lesions and the cytologic reports of 57 lesions. Results were compared to the final histopathological diagnoses. 81 of the 84 lesions (96%) were observed as a local abnormality at USG thereby missing three lesions. Also, the sensitivity and specificity of FNAC were reported as 92 and 83%, respectively. There were no false-negative malignancies in the three modalities (USG, mammography and FNAC) combined. They concluded that active and critical use of various modalities could cut down the number of surgical biopsies of benign breast lesions [40].

## CONCLUSION

Breast USG not only helps in differentiating solid from the cystic lesion but also plays important role in characterizing breast lesion. USG features suggestive of malignancy include spiculations, hypoechogenicity, microlobulations, internal calcifications, shadowing, taller than wider, angular margins among others. USG features suggestive of benignity include round or oval shape, well defined margins with thin echogenic capsule, hyperechogenicity, absent of posterior shadowing and non-calcified nodule. Thus, the ability to characterize lesion on USG help to determine the next step in patient care. Ultrasound is valuable in evaluating the breast lesions in patients with benign and malignant diseases. However a definite diagnosis is still dependent on histopathology.

The result of the study in terms of both high specificity and negative predictive value revealed sonography can be used to accurately classify some solid lesions as benign, allowing imaging follow-up rather than biopsy substitute. USG is an ideal imaging modality due to its cost

effectiveness and non ionizing radiation potential. Thus, this correlative study of USG findings with fine needle aspiration for cytology describes reliable, frequent and reproducible features for differentiating benign from malignant breast masses. It is hoped that the outcome of this research would be useful for early diagnosis and management of breast lump in perspective of Nepal. Cancer edification, screening and early detection are the essential elements to influence the diagnosis, treatment and prognosis of breast cancer in Nepal. Breast cancer alertness and clinical breast examination are key tools for early detection in our resource of narrow context. The diseases can be cured in majority of the cases if diagnosed in early stages. However, diagnoses of two breast masses were missed by USG which were correctly diagnosed by FNAC. Thus both the diagnostic tools should be considered complementary on the basis of clinical findings and based on experience one should choose either one of or both the tools. Sonography can be used to accurately assess and classify some solid lesions as benign, allowing imaging follow-up rather than cytology/biopsy surrogate.

## REFERENCES

- Giordano SH. A review of the diagnosis and management of Male breast cancer. *Oncologist*, 2005; 10: 471-479.
- World Health Organization, "Fact Sheet No. 297: Cancer," 2006.
- Garcia M et al. *Global Cancer Facts & Figures*; 2007. Atlanta, GA: American Cancer Society.
- Ferlay J et al. Estimates of worldwide burden of cancer in: GLOBOCAN 2008. *Int J Cancer*, 2010; 15; 127: 2893-917.
- Houssami N et al. Accuracy of combined breast imaging in young women. *The Breast*, 2002; 11: 36-40.
- Martelli G et al. Diagnostic efficiency of physical examination, mammography, fine needle aspiration cytology (triple test) in solid breast lumps: an analysis of 1708 consecutive cases. *Tumori*, 1990; 76: 476-79.
- Giard RW and Hermans J. The value of aspiration cytologic examination of the breast. A statistical review of the medical literature. *Cancer*, 1992; 69: 2104-10.
- Jayaram G et al. Cytological analysis of breast lesions: A review of 780 cases. *Malaysian Journal of Pathology*, 1996; 18: 81-87.
- Tiwari M. Role of fine Needle aspiration cytology in diagnosis of breast lumps. *Kathmandu Univ Med J.*, 2007; 5: 215-17.
- Kocjan G. Needle aspiration cytology of the breast: current perspective on the role in diagnosis and management. *Acta Med Croatica*, 2008; 62: 391-401.
- Karin L. Breast. In: Svante RO, Greogory FS, Darrel W, editors. *Fine Needle Aspiration Cytology*. 4th ed. India: Elsevier Ltd; 2005; 165-225.
- Tse GM and Tan PH. Diagnosing breast lesions by fine needle aspiration cytology or core biopsy: which is better? *Breast Cancer Res Treat.*, 2010; 123: 1-8.
- Ghazala M et al. Sonomammography for evaluation of solid breast masses in young patients. *J Ayub Med Coll Abbottabad*, 2006; 18: 34-37.
- Stavros AT et al. Solid breast nodules: use of sonography to distinguish between benign and malignant lesions. *Radiology*, 1995; 196: 123-134.

15. Gordon PB. Ultrasound for breasts cancer screening and staging. *Radiol. Clin. North Am.*, 2002; 40: 431-41.
16. Kailash S et al. The accuracy of Ultrasound in characterization of palpable breast lumps. *JK Science*, 2008; 10: 186-88.
17. Lister D et al. The accuracy of breast ultrasound in the evaluation of clinically benign discrete, symptomatic breast lumps. *Clin Radiol*, 1998; 53:490-492.
18. Fasching PA et al. Influence of mammographic density on the diagnostic accuracy of tumor size assessment and association with breast cancer tumor characteristics. *Eur J Radiol*, 2006; 60:398-404.
19. Rabhar G et al. Benign versus malignant solid breast masses: US differentiation. *Radiology*, 1999; 213: 889-894.
20. Pande AR et al. Predictive value of ultrasonography in the diagnosis of palpable breast lump. *Kathmandu University Medical Journal*, 2003; 1: 78-84.
21. Watermann DO et al. Ultrasound morphology of invasive lobular breast cancer is different compared with other types of breast cancer. *Ultrasound Med Biol*, 2005; 31:167-174.
22. Aho M et al. Correlation of sonographic features of invasive ductal mammary carcinoma with age, tumor grade, and hormone-receptor status. *J Clin Ultrasound*, 2013; 41:10-17.
23. Soon PS et al. Echogenicity of breast cancer: is it of prognostic value? *Breast*, 2004; 13:194-199.
24. Ekblom A et al. Epidemiologic correlates of breast cancer laterality (Sweden), *Cancer Causes Control*, 1994; 5: 510-516.
25. Goodman MT et al. Comparative epidemiology of breast cancer among men and women in the US, 1996 to 2000, *Cancer Causes Control*, 2006; 17 :127-136;
26. Perkins CI et al. Association between breast cancer laterality and tumor location, United States, 1994-1998, *Cancer Causes Control*, 2004; 15: 637-645.
27. Roychoudhuri R et al. Cancer and laterality: a study of the five major paired organs (UK), *Cancer Causes Control*, 2006; 17: 655-662.
28. Hallberg O and Johansson O. Sleep on the right side-Get cancer on the left? *Pathophysiology*, 2010:157-60.
29. Wilting J and Hagedorn M. Left-right asymmetry in embryonic development and breast cancer: common molecular determinants? *Curr Med Chem.*, 2011; 18: 5519-27.
30. Weiss HA et al. Laterality of breast cancer in the United States, *Cancer Causes Control*, 1996; 7: 539-543.
31. Brewster DH et al. Left-sided excess of invasive cutaneous melanoma in six countries, *Eur. J. Cancer*, 2007; 43: 2634-2637.
32. Adesunkanmi AR and Agbakwuru EA. Benign breast disease at Wesley Guild Hospital, Ilesha, Nigeria. *West Afr J Med.*, 2001; 20:146-51.
33. Titus-Ernstoff L et al. Left-handedness in relation to breast cancer risk in postmenopausal women, *Epidemiology*, 2008; 11: 181-184.
34. Ramadhani MK et al. Innate left handedness and risk of breast cancer: case-cohort study. *BMJ*, 2005; 331: 882-883.
35. Yang WT et al. Role of high frequency ultrasonography in the evaluation of palpable breast masses in Chinese women: alternative to mammography? *J Ultrasound Med.*, 1996; 15:637-44.
36. Skaane P et al. Interobserver variation in the interpretation of breast imaging: Comparison of mammography, ultrasonography and both combined in the interpretation of palpable non calcified breast masses. *Acta Radiol*, 1997; 38: 497-502
37. Soo MS et al. Negative predictive value of sonography with mammography in patients with palpable breast lesions. *AJR*, 2001; 177:1167-1170.
38. Jan M et al. Triple assessment in the diagnosis of breast cancer in Kashmir. *Indian J Surg.*, 2010; 72: 97-103.
39. Takhellambam YS et al. Comparison of ultrasonography and fine needle aspiration cytology in the diagnosis of malignant breast lesions. *J Clin Diagn Res.*, 2013; 7: 2847-50.
40. Reinikainen HT et al. Contribution of ultrasonography and fine-needle aspiration cytology to the differential diagnosis of palpable solid breast lesions. *Acta Radiol.*, 1999;40:383-89.